




Appendix B: Pap Sampling Technique

Slide Labeling is Mandatory

Use a **pencil** to print the **woman's date of birth and surname** on the **frosted** end of the slide. Include at least the first seven letters if the surname has more than 7 letters. The name and DOB must be easy to read, written correctly and match the name and DOB on the requisition.



Single Slide Method

Please use the single slide method. Multiple slides from one woman are not necessary or cost effective. Women with a double cervix are the obvious exception.

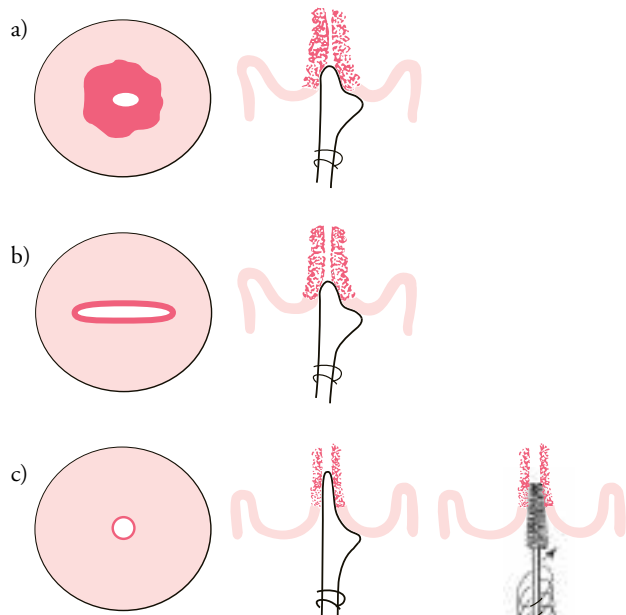
If two sites are sampled (i.e. cervix and endocervix), they can be applied side-by-side on the same side of a single slide.

Variations in Cervical Transformation Zone

A major cause of a false negative test is failure to sample the transformation zone (squamocolumnar junction).

The transformation zone is the region lying between the columnar epithelium of the endocervix and the mature squamous epithelium of the ectocervix. It is here that carcinogens act upon the squamous metaplastic cells of the transformation zone to cause squamous dysplasia and squamous carcinoma.

Generally, during the reproductive years, the transformation zone lies on the ectocervix. Post-menopausally, it recedes within the endocervix.



The location of the squamocolumnar junction is dependent on the woman's age, parity, hormonal status and any previous surgery.

If squamocolumnar junction is visible, sample with a spatula. If not visible (i.e. in the canal), sample with the elongated end of spatula or cytobrush.

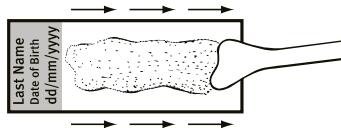
- a) Reproductive age group, nulligravida; squamocolumnar junction often visible on ectocervix lateral to os. Os (small, round or oval). Sample with spatula.
- b) Reproductive age group, parous; squamocolumnar junction often at or near external os. Sample with spatula.
- c) Post menopause. Squamocolumnar junction often in canal. Cervical os often smaller. Sample with elongated end of spatula and cytobrush.

Obtaining the Sample

1. Gently insert a sterile, pre-warmed speculum to visualize cervix.
A small (tiny) amount of lubricant may be used on the lower bill of the speculum for post menopausal women.
2. Gently cleanse the cervix with cotton pledget if obscured with discharge or secretions.
3. Identify extent of transformation zone and probable squamocolumnar junction.

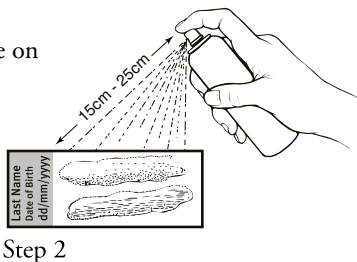
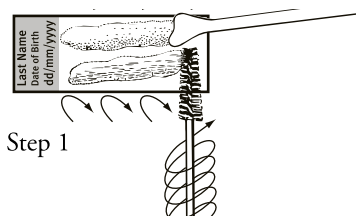
If Squamocolumnar Junction is Visible

- Rotate a spatula 360° once to obtain a single sample.
- Smear the sample onto the labeled slide.
- Fix the sample immediately (before it is air-dried) using a cytology spray fixative. Hold the fixative 15-20 cm (6 to 8 inches) away from the slide and evenly spray the slide by depressing the plunger 2 or 3 times. (See Step 2 below).



If Squamocolumnar Junction is Not Visible

- First use a spatula for the exocervical specimen.
- Then use a cytobrush or the elongated end of the spatula for the endocervical sample. Rotate cytobrush 180° only.
- Place both specimens side-by-side lengthwise on a single slide and fix immediately.



Cautions

- Use of the cytobrush is not recommended in pregnant women.
- If a clinically suspicious lesion is seen, biopsy immediately.
- If the patient is menstruating or infection is present reschedule exam.
- Irregular bleeding may be a symptom of gynecological malignancy. Pelvic examination with lower genital tract and appropriate investigation is indicated.

The use of cotton swabs for sampling is associated with cellular trapping and distortion and is not recommended.

Equipment and Supplies

Equipment and supplies	Order from:
Examination table	Medical supplier
Good illumination	
Bi-valve speculum (various sizes)	
Endocervical brush	
Cytology spray fixative (e.g. cytospray)	
Extended-tip spatula	Cervical Cancer Screening Laboratory (supplied free of charge)
Glass microscope slide with frosted end	<ul style="list-style-type: none"> • See the supply order form at www.screeningbc.ca/cervix → For Health Professionals • Fax order form to 604-707-2606
Container for transporting slide to the lab	
Requisition form	
Lead pencil for labeling slide	Stationery supplier

Source: BC Cancer Agency. Screening for cancer of the cervix – An office manual for health professionals. (10th Ed). 2013.