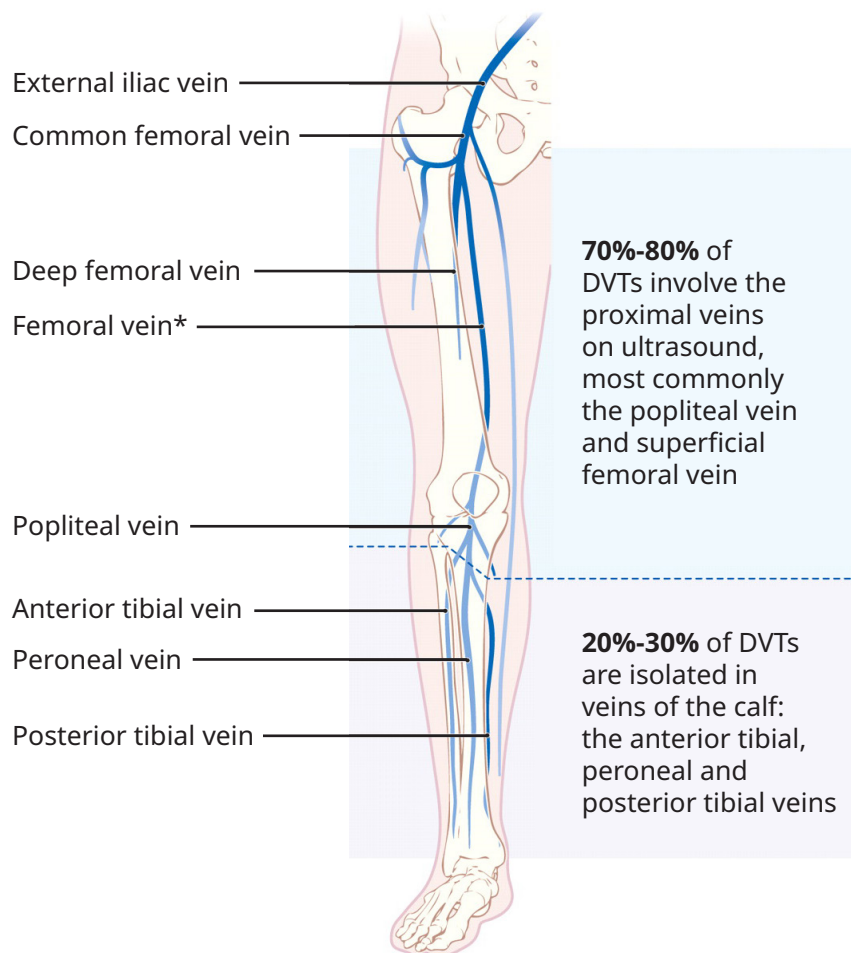




## Appendix A: Proximal and Distal DVT



\* often referred to as “superficial femoral vein” however it is a deep vein of the leg.

Figure adapted from Diagnosis and treatment of deep-vein thrombosis, CMAJ October 24, 2006 175 (9) 1087-1092; DOI: <https://doi.org/10.1503/cmaj.060366>